


SkinNeedle

2mm 34G: Where Comfort Meets Performance

2.0 mm 34G Needle

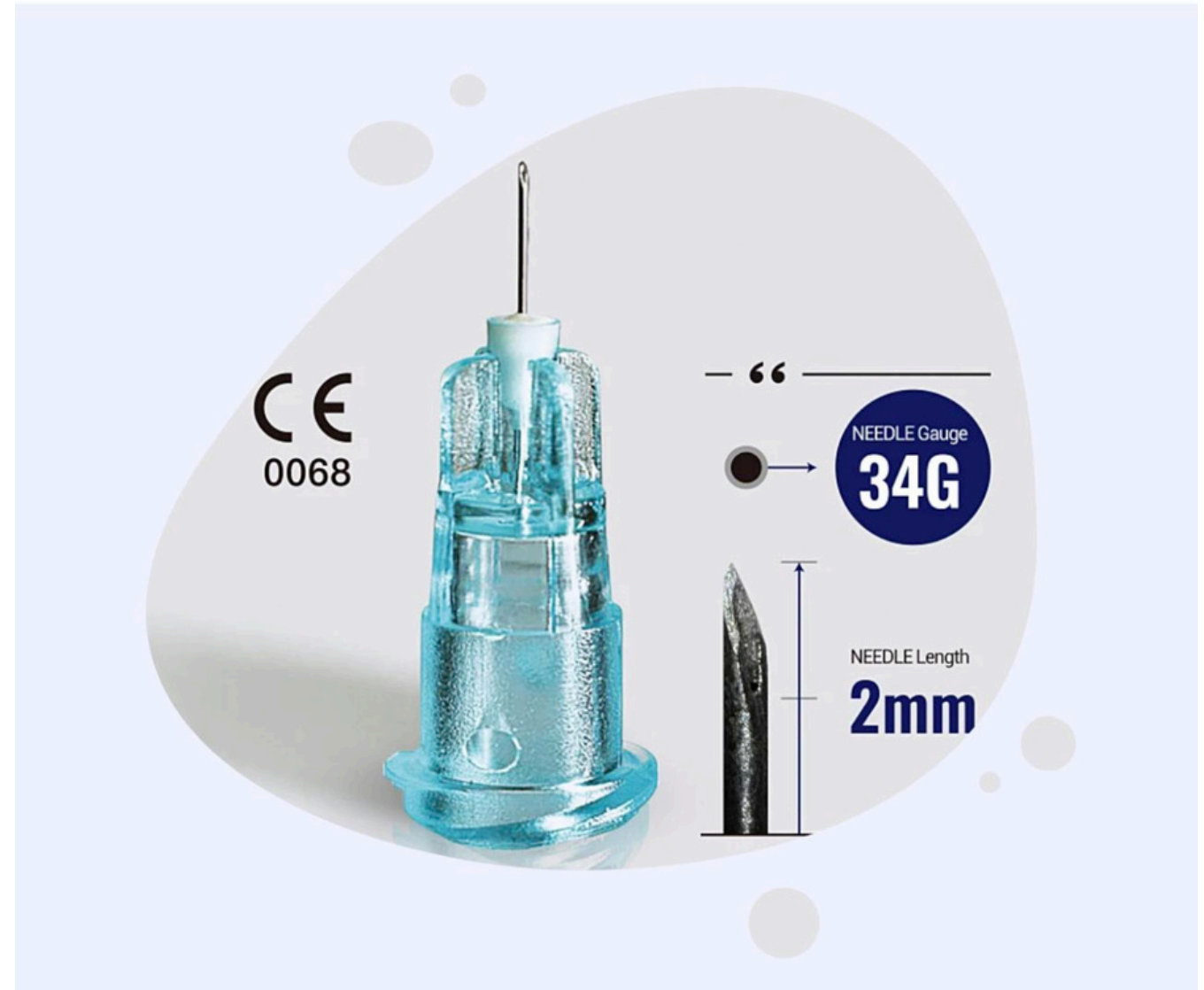

INTRODUCTION

Length 2.0mm

Gauge Certification 34G

Configuration GMP, ISO13485



BENEFIT



For Practitioners

Quicker &
More accurate procedures

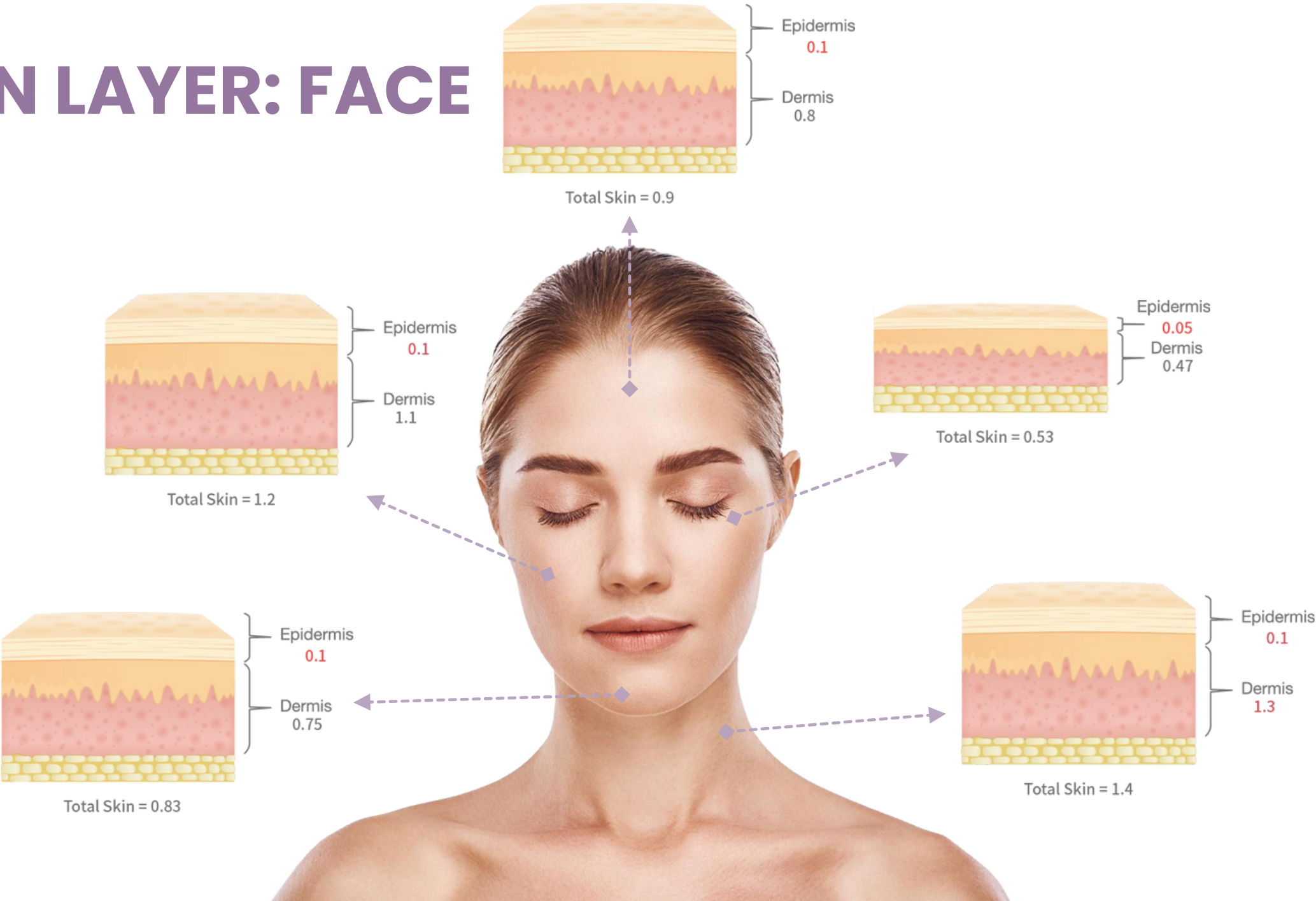
For Patients

Less Pain

An intradermal injection is a medical procedure that involves administering a small amount of medication or substance into the dermal layer of the skin. Our focus was on identifying the most suitable injection needle for the precise intradermal administration of skin boosters, ensuring accurate placement and facilitating ease and convenience during the procedure. This enhancement in practitioner convenience allows for quicker and more accurate procedures.

Intradermal injections frequently cause more pain and discomfort compared to other types of injections due to the higher density of nerve endings in the dermal layer, in contrast to subcutaneous tissue or muscle. This heightened patient sensitivity underscores the need for effective pain reduction methods.

SKIN LAYER: FACE



SKIN LAYER: FACE

| Area | Epidermis(mm) | Dermis(mm) | Total Skin Thickness(mm) |
|-------------|---------------|------------|--------------------------|
| Forehead | 0.1 | 0.8 | 0.9 |
| Periorbital | 0.05 | 0.47 | 0.53 |
| Cheeks | 0.1 | 1.1 | 1.2 |
| Chin | 0.08 | 0.75 | 0.83 |
| Neck | 0.1 | 1.3 | 1.4 |

<Aesthetic & Spa May 2010 p98-100>

SKIN LAYER: FACE


The typical depth of facial skin varies anatomically, with the epidermis being relatively thin compared to other body parts, measuring approximately 0.1 to 0.5 mm in the facial area.

The dermal layer in the facial region is thicker than the epidermis, ranging from 1 to 2 mm in depth.

Average thickness : 1.2mm

Epidermis : 0.1mm

Dermis : 1.2~2.0mm for face



SKIN LAYER: SCALP

The epidermis is a very thin layer, just 0.1 mm thick.

It combines with the underlying dermis to form an outer epithelial covering and is therefore continuous with the epidermis itself. Like the epidermis, it is made up of several layers of cells.



Epidermis: 0.1 mm.

The diagram illustrates a cross-section of the scalp skin. The epidermis is the thin, yellowish, wavy layer on top. Below it is the dermis, a thicker, reddish layer with a bumpy, cellular appearance. A blue circle with a white arrow points to the epidermis, and another blue circle with a white arrow points to the dermis.

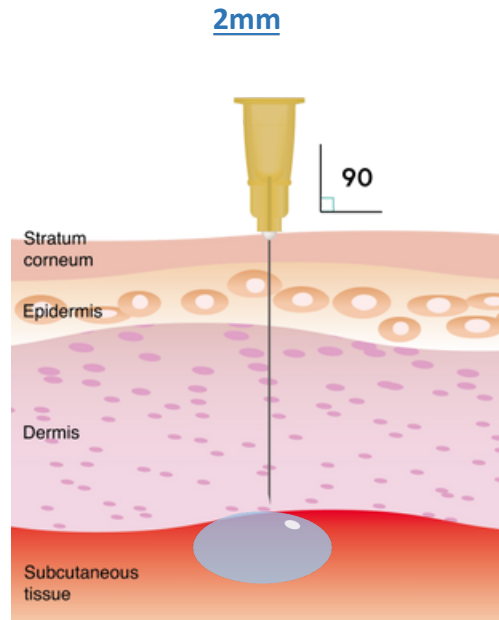
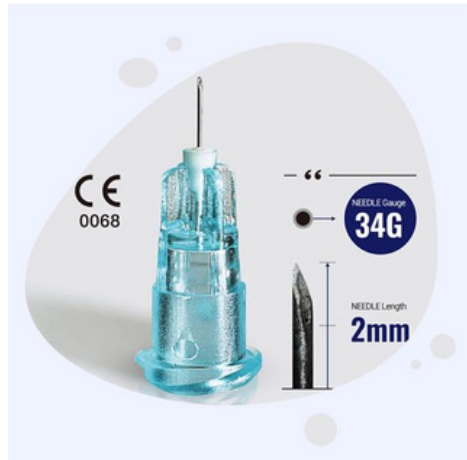Dermis: 2.5 mm.

The dermis is the highly vascularized area of the scalp. The average thickness

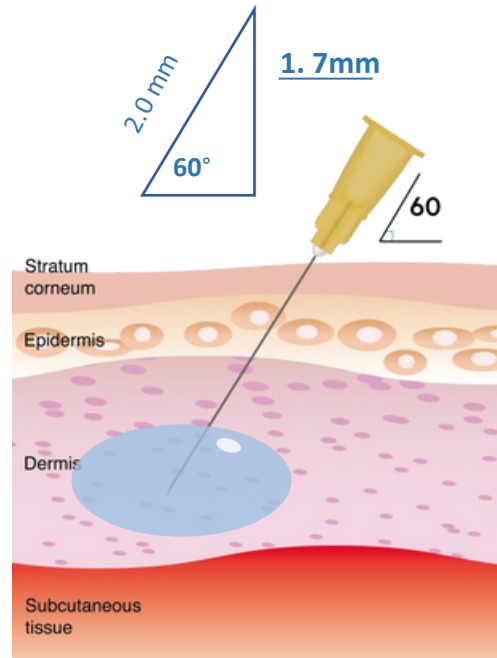
This is where the hair follicles, the roots of the hair, are located. Surrounded by a network of blood vessels, it provides a rich supply of energy essential for hair growth, survival, and stimulation of cell regeneration.

TECHNIQUE

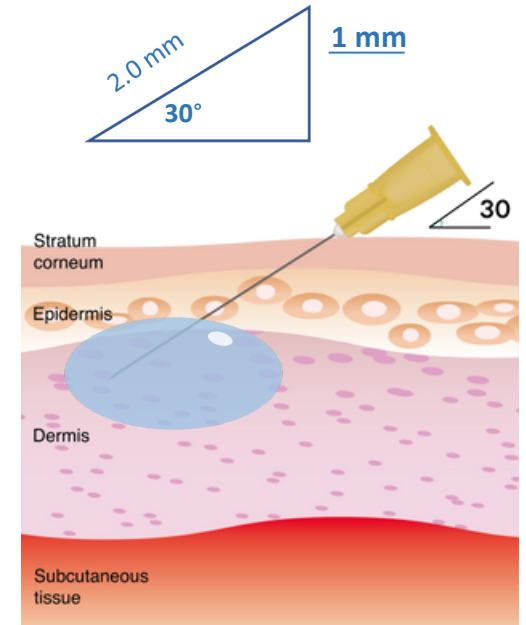
2mm, The Right Target to Dermis!



Deep dermis
~ Subcutaneous



Mid Dermis



Low Dermis

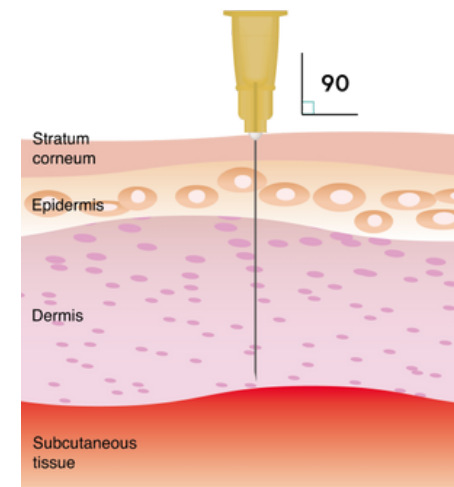
TIPS BY USE

■ Dermal Skin booster (~90°)

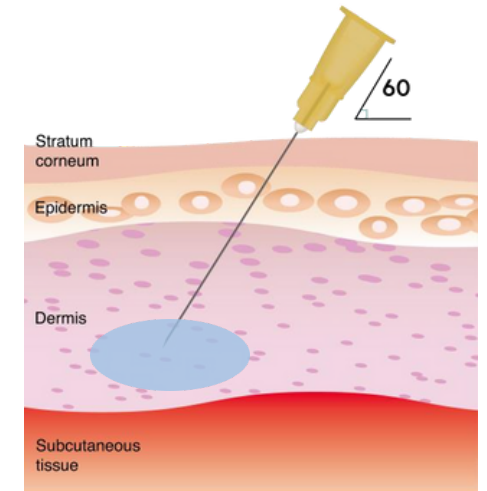
- Most widely used
- Superficial ~ deep dermis ~ subcutaneous layer

■ Scalp Booster (90°)

- The use of AI 2.0 Needle is effective because it is an area that causes a lot of pains.
- Mainly used at vertical degree



Scalp Booster



Skin Booster

THANK YOU

SkinNeedle

2mm 34G: Where Comfort Meets Performance

www.lpgclinicswholesale.com | info@lpgclinicswholesale.com